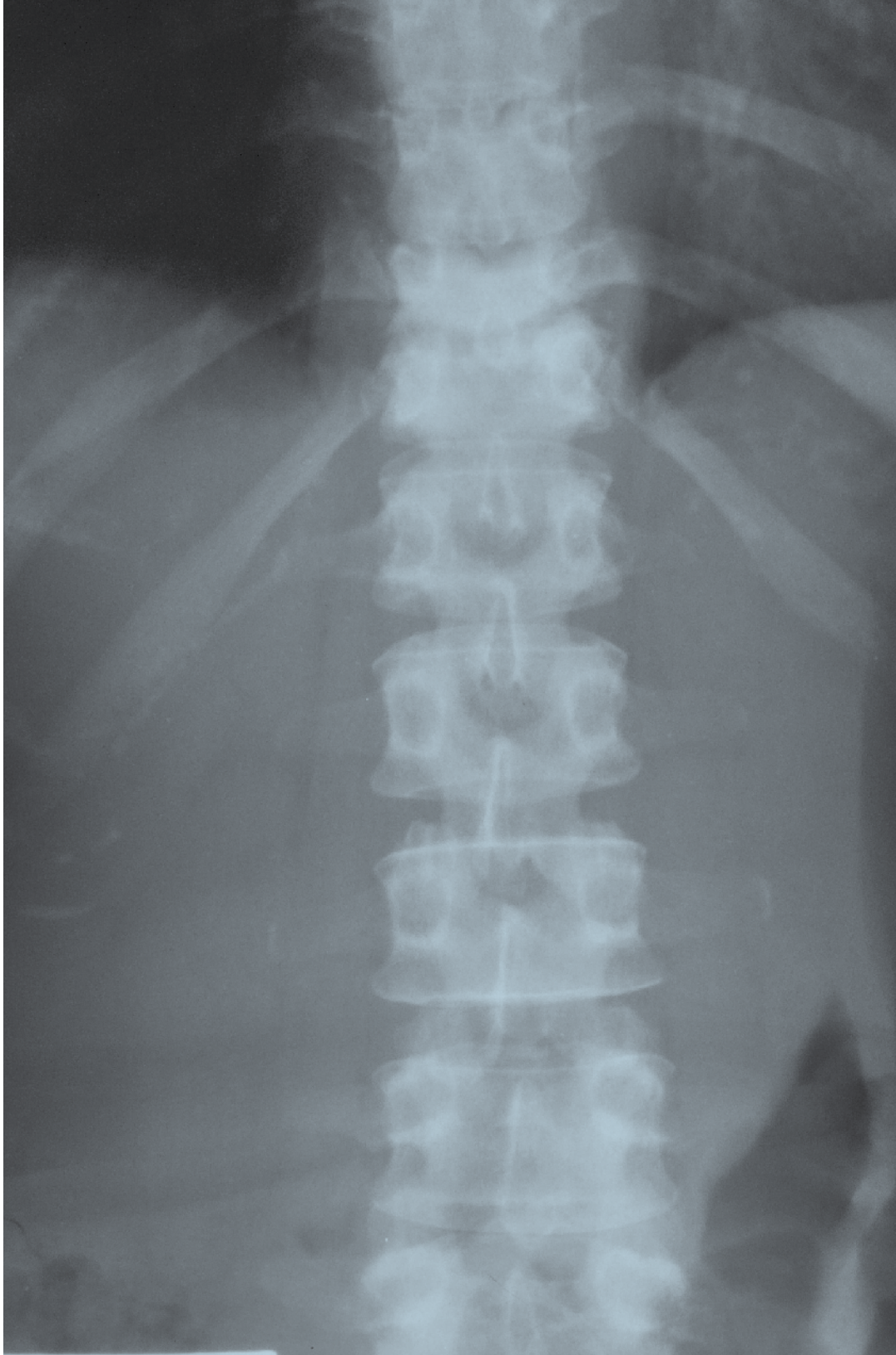


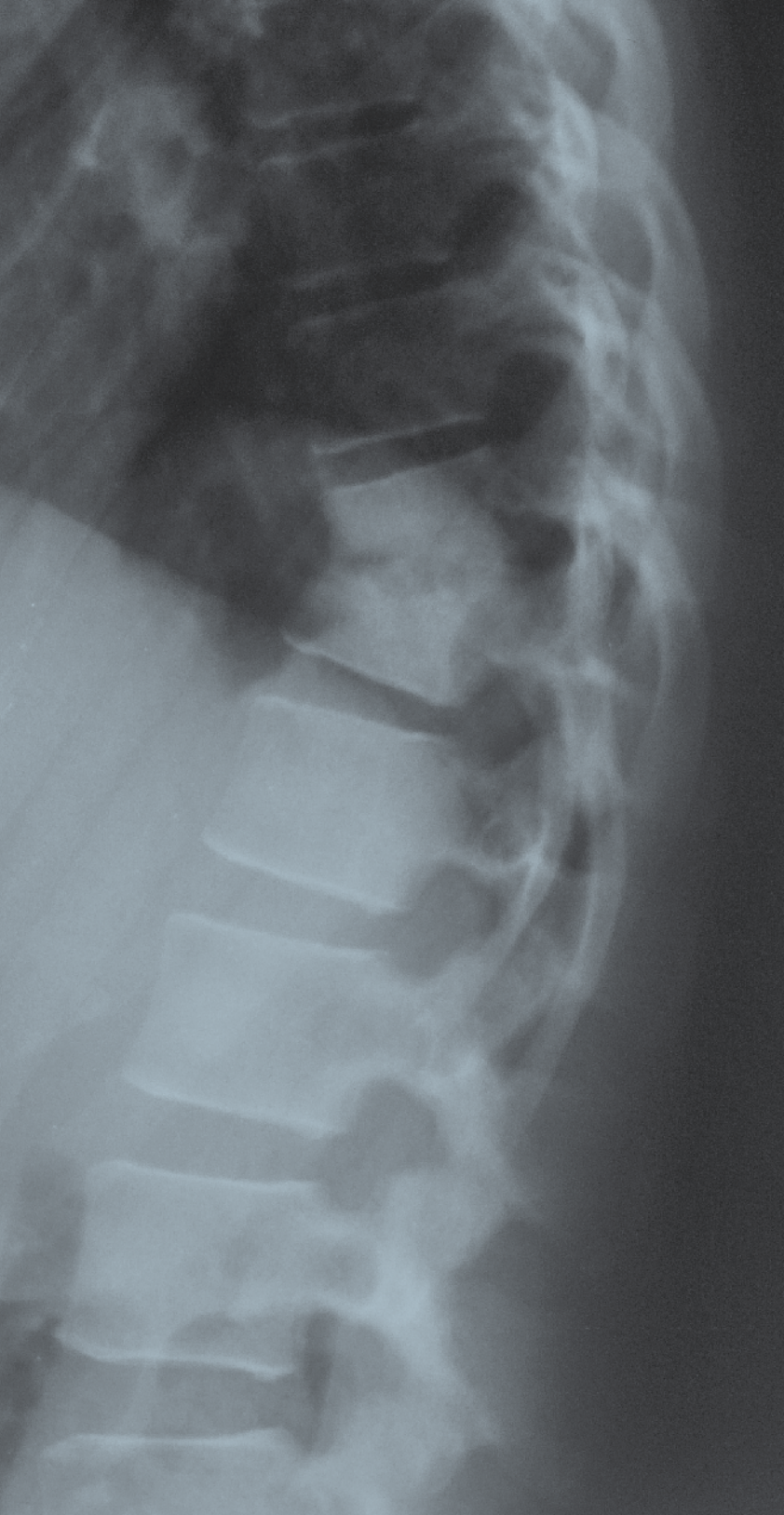
# RADIOGRAPHIC QUIZ

50 year-old woman with back pain.  
Spine radiographs of the thoracolumbar junction  
are shown below.



# • *Please respond ...*

*Julio Manuel Díaz Riverol<sup>1</sup>*



- Please answer the following with TRUE or FALSE regarding the salient abnormality.

- Multiple vertebral bodies are involved.*
- The intervertebral disc is involved.*
- The spinal cord is at risk.*
- There is paravertebral extension of the salient pathological process.*
- There is evidence of reactive sclerosis with anterior wedging and collapse of the vertebral bodies.*

Answers on page 31

---

<sup>1</sup> MD, Radiologist, Belize Healthcare Partners, Belmopan Medical Imaging Center  
Email: diazriverol@hotmail.com