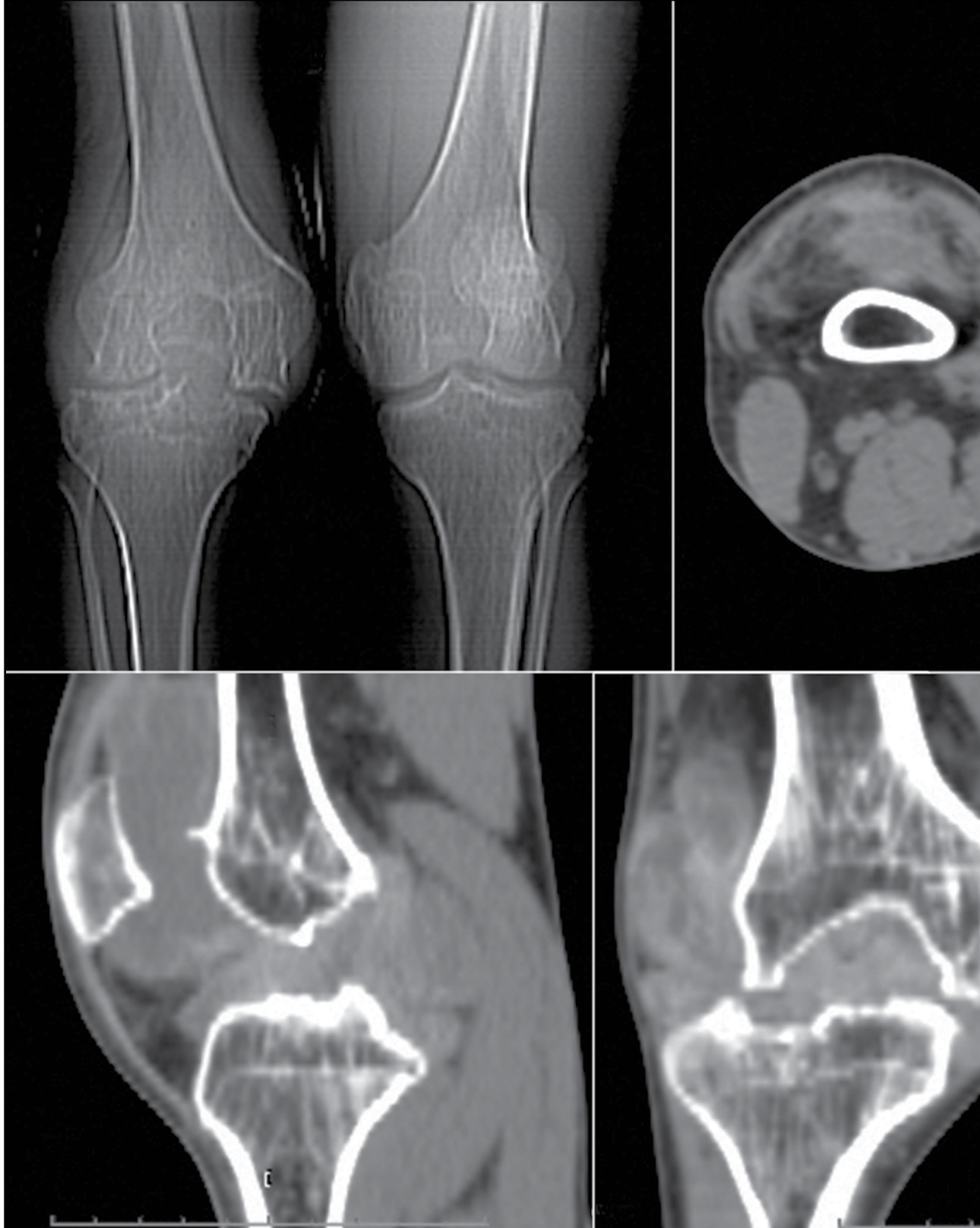


RADIOGRAPHIC QUIZ

18-year-old white male presenting with intermittent bilateral knee pain for the past 5 years, increasing in severity recently.

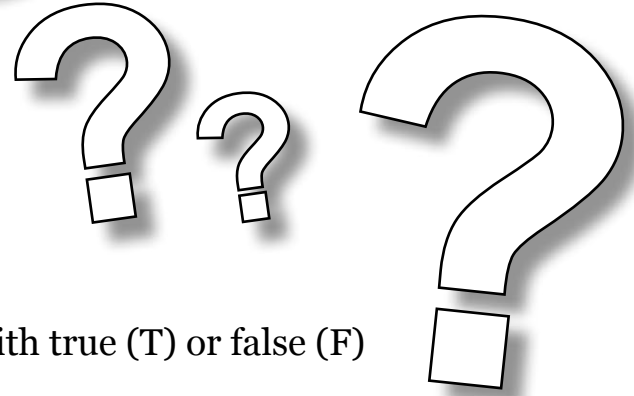
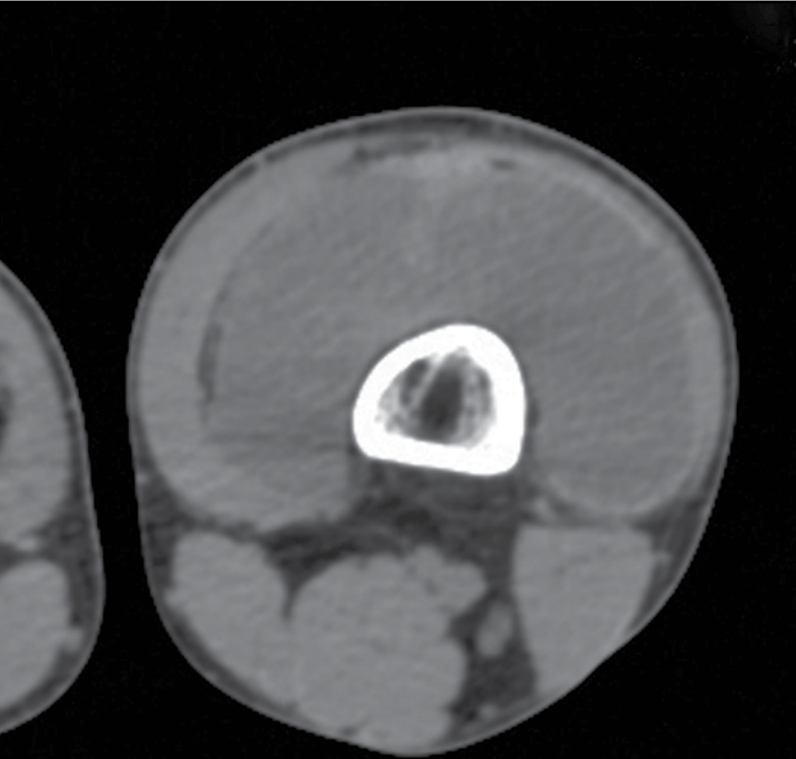
CT topogram image of both knees, axial and reformatted images are presented.



• Please respond ...



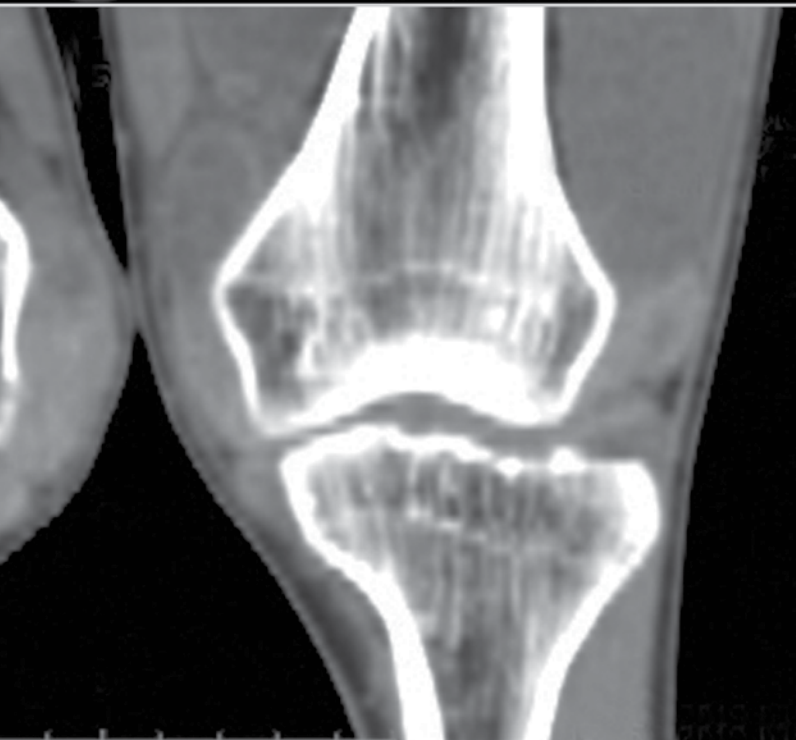
Julio Manuel Díaz Riverol¹



...with true (T) or false (F)

Which of the following findings are present?

- Joint space irregularity and narrowing*
- Subchondral sclerosis*
- Subchondral cyst formation*
- Periarticular osteopenia*
- Epiphyseal overgrowth*
- Joint effusion*
- Widening notch of the distal femur*
- Erosion of joint margins*



Considering the patient's age, race and tomographic findings which is the most likely diagnosis.

- A. Degenerative osteoarthritis*
- B. Hemophilic arthropathy*
- C. Primary synovial chondromatosis*
- D. Pigmented villonodular synovitis*

Answers on page 39

¹ MD, Radiologist.
Belmopan Medical Imaging Center.
Email: diazriverol@hotmail.com